

Aortic Atherosclerosis and Embolic Events

Muhamed Saric & Itzhak Kronzon

Current Cardiology Reports

ISSN 1523-3782

Curr Cardiol Rep

DOI 10.1007/s11886-012-0261-2

VOLUME 14 | NUMBER 1 | FEBRUARY 2012

CURRENT **CARDIOLOGY** REPORTS

EDITOR-IN-CHIEF Steven E. Nissen
ASSOCIATE EDITOR Raimund Erbel

Cardiac PET, CT, and MRI
Section Editor ▪ Stephan Achenbach

New Therapies for Cardiovascular Disease
Section Editor ▪ Ken W. Mahaffey

Diabetes and Cardiovascular Disease
Section Editor ▪ Nathan D. Wong

Current Cardiology Reports is indexed by MEDLINE

CMG Current Medicine Group is now an imprint of Springer Science+Business Media, LLC

AVAILABLE ONLINE
www.Springerlink.com

Your article is protected by copyright and all rights are held exclusively by Springer Science+Business Media, LLC. This e-offprint is for personal use only and shall not be self-archived in electronic repositories. If you wish to self-archive your work, please use the accepted author's version for posting to your own website or your institution's repository. You may further deposit the accepted author's version on a funder's repository at a funder's request, provided it is not made publicly available until 12 months after publication.

Aortic Atherosclerosis and Embolic Events

Muhamed Saric · Itzhak Kronzon

© Springer Science+Business Media, LLC 2012

Abstract Aortic plaques are a manifestation of the general process of atherosclerosis in which there is a progressive accumulation of cholesterol and other lipids in the intimal-medial layer of the aorta with secondary inflammation, repetitive fibrous tissue deposition, and eventually luminal surface erosions and appearance of often mobile thrombi protruding into the lumen of the aorta. Aortic plaques may give rise to two types of emboli: thromboemboli and atheroemboli (cholesterol crystal emboli). Thromboemboli are relatively large, tend to occlude medium to large arteries, and cause strokes, transient ischemic attacks, and renal infarcts and other forms of peripheral thromboembolism. Cholesterol crystal emboli are relatively minute, tend to occlude small arteries and arterioles, and may cause the blue toe syndrome, new or worsening renal insufficiency, gut ischemia, etc. Transesophageal echocardiography remains the gold standard for visualization of aortic plaques in the thoracic aorta. There are no proven

therapies for aortic embolism per se; general atherosclerosis management strategies are recommended.

Keywords Atherosclerosis · Aorta · Thromboembolism · Atheroma · Plaque · Atheroembolism · Cholesterol embolization syndrome · Transesophageal echocardiography · 3D echocardiography · Computed tomography · Magnetic resonance imaging · Stroke · Transient ischemic attack

Introduction

The anatomic findings of atherosclerosis have been known to pathologists for centuries. For instance, the description of aortic atherosclerosis on autopsy published in 1755 by the Swiss anatomist Albrecht von Haller [1] is surprisingly modern. He noted aortic atherosclerotic plaques in various stages of development, some soft and filled with yellowish pulsatous material, some leathery and yet others calcified and hard as a bone. He was the first to apply the term “atheroma” to soft mushy atherosclerotic plaques. To him the content of these plaques was “not dissimilar to that seen in atheromas” (“non dissimilis ejus qui in atheromate reperitur”). The term atheroma (αθήρωμα) had previously been used by the ancient Greek writers to describe any tumor or swelling filled with gruel-like material (αθήρη–athērē: gruel, crushed grains).

In 1833, the German-French surgeon Johann (Jean) Lobstein [2] introduced the term “arteriosclerosis” (artériosclérose) to emphasize the stiffening of the arterial wall in the course of atherosclerosis. He noted that the disease particularly affects the aortic arch and its branches, the descending thoracic and abdominal aorta, and the arteries in the lower extremities but spares those in the upper extremities. In 1904, the German internist Felix Jacob Marchand [3],

M. Saric
Leon H. Charney Division of Cardiology,
New York University Langone Medical Center,
New York, NY, USA

I. Kronzon
Department of Cardiovascular Medicine, Lenox Hill Hospital,
New York, NY, USA

M. Saric (✉)
Noninvasive Cardiology Laboratory,
New York University Langone Medical Center,
560 First Avenue,
New York, NY 10016, USA
e-mail: muhamed.saric@nyumc.org

I. Kronzon
Lenox Hill Interventional Cardiac and Vascular Services,
Noninvasive Cardiology, 2E, 100 East 77th Street,
New York, NY 10075, USA
e-mail: ikronzon@lenoxhill.net

coined the phrase “atherosclerosis” by combining the terms “atheroma” of von Haller and “arteriosclerosis” of Lobstein.

Pathophysiology of Atherosclerosis

Atherosclerosis is a complex progressive lifelong disorder affecting the intimal and medial layers of the arterial tree whose pathophysiology is yet to be fully elucidated. The well-established independent risk factors for atherosclerosis include age, male gender, tobacco use, diabetes mellitus, high levels of serum low-density lipoproteins, low levels of high-density lipoproteins, systemic hypertension, and family history [4]. Additional risk factors may include viral and bacterial infections of the endothelium, and elevated blood levels of markers of inflammation (e.g., C-reactive protein) or thrombogenicity (e.g., plasma fibrinogen) [5, 6].

Risk factors promote plaque formation, the hallmark of atherosclerosis, through vascular endothelial injury, accumulation of low-density lipoprotein cholesterol and its subsequent oxidation in the vascular wall, and through activation of an inflammatory cascade. According to the American Heart Association consensus statement, plaque histology progresses through six stages, which are labeled using Roman numerals I through VI [7]. The plaque histology classification is summarized in Table 1.

Early atherosclerosis comprises stage I, II, and III; such lesions develop in childhood and adolescence. Stage I (initial lesion) and stage II (fatty streak) are primarily characterized by intracellular accumulation of atherogenic lipids within macrophage foam cells. In stage III (intermediate lesion), there are also small extracellular lipid pools. The three stages of early atherosclerosis are usually clinically silent and often invisible on standard arterial imaging techniques.

Advanced atherosclerosis spans stages IV, V, and VI; such lesions typically develop in the middle age and increase in complexity particularly in the elderly. Advanced atherosclerotic lesions are characterized by a continued increase in the amount of extracellular lipid in the intimal layers of the wall and the development of a lipid core, activation of smooth muscle and inflammatory cells, and alterations in the lesions' luminal surface. At stage IV, the

lesion is mostly comprised of a lipid core (atheroma). In stage V (fibroatheroma), there is a progressive increase in the amount of fibrous tissue in and around the lipid core. Finally, at stage VI (complex atheroma), the plaque surface erodes (ulcerates) and the lesion become overlaid with platelet and fibrin clots. At stage V and VI, variable amounts of calcium in the form of apatite may accumulate in the lesions; thus, plaque calcification is a marker of advanced atherosclerosis.

An increase in the size of the lipid core in an advanced plaque and/or clot formation on its surface may lead to vessel stenosis, complete occlusion, and embolism or secondary incorporation of the clot into the plaque after re-endothelialization. Alternatively, the inflammatory process may lead to weakening of the arterial wall and subsequent aneurysm formation.

It is at the histologically advanced stages that atherosclerosis becomes clinically overt and visible on standard imaging techniques. Clinical manifestations are dependent on the size of the affected artery, overall plaque burden, plaque size, plaque stability (its propensity to burst open into the surrounding lumen; such propensity is not directly proportional to plaque size), and thrombogenicity of the surrounding blood.

Pathophysiology of Aortic Atherosclerosis

The aorta is a large-diameter vessel and progressive bulging into the lumen of even large and/or thrombosed atherosclerotic plaques typically does not lead to occlusive phenomena that are frequently seen in smaller arteries (e.g., stable angina pectoris or myocardial infarction in the coronary arterial circulation). Instead, the typical manifestation of atherosclerosis of the aorta is plaque embolism [8••]. Atherosclerosis may also contribute to the development of aortic aneurysms [9].

The severity of atherosclerosis progressively increases from the ascending aorta toward the abdominal aorta. The infrarenal aorta is particularly susceptible to the development of aortic aneurysms; atherosclerosis either contributes to the development of abdominal aortic aneurysms or at least shares similar risk factors with them. The clinical significance of thoracic and abdominal aortic atherosclerosis is primarily related to plaque embolism.

Table 1 Histologic classification of atherosclerotic lesions

Early lesions (childhood and early adulthood)			Late lesions (middle age and adulthood)		
Stage I	Stage II	Stage III	Stage IV	Stage V	Stage VI
Initial lesion	Fatty streak	Intermediate lesion	Atheroma	Fibroatheroma	Complex plaque
Small amounts of intracellular lipid deposits	Larger amounts of intracellular lipid deposits	Small extracellular lipid pools	Extracellular lipid core	Lipid core + fibrotic changes	Surface defects (ulcerations, hemorrhage, thrombus)
Usually clinically silent			Clinically silent or overt		

Aortic plaque embolism takes two forms: thromboembolism and atheroembolism (cholesterol embolization syndrome). In both instances there is embolization from the aorta to its branches (arterio-arterial embolism). However, the two phenomena differ in the size and content of emboli, the rate of occurrence, and their clinical manifestations, prognosis, and treatment [10]. Clinically, thromboembolism is much more frequent than atheroembolism.

In thromboembolism, the embolic material contains fragments of a thrombus that forms atop a stage VI atheromatous plaque in the aorta. Thromboemboli travel distally to occlude large to medium-sized arteries. In thromboembolism there is typically an abrupt release of a solitary or a few large emboli leading to severe ischemia of target organs [11].

Atheroembolism (cholesterol embolization syndrome), on the other hand, refers to embolization of the contents (primarily cholesterol crystals) of an advanced atherosclerotic plaque in the aorta to distal small to medium-sized arteries. Atheroemboli inflict end-organ damage by both mechanical plugging and an inflammatory response. Atheroembolism is frequently characterized by a multitude of small emboli (showers of microemboli) occurring in recurrent waves. Danish physicians Fenger et al. [12] (in 1844) and Panum [13] (in 1862) appear to have published the first descriptions of atheroembolism.

Both thromboembolism and atheroembolism may occur either spontaneously or following an iatrogenic procedure in the aorta (e.g., arteriography, intra-aortic balloon placement, percutaneous intervention, or surgery) [14, 15].

Iatrogenic plaque disruption often significantly increases the morbidity and mortality of aortic procedures (e.g., the transcatheter aortic valve insertion) [16]. Clinically overt aortic embolism is much less frequent than the silent one after iatrogenic plaque disruption as judged by transcranial Doppler ultrasonography or brain magnetic resonance imaging (MRI) [17].

Atherosclerotic Plaque Imaging

Ultrasonography, computed tomography (CT), and MRI are the principal means of imaging atherosclerotic plaques in the aorta [18]. The role of other imaging techniques (e.g., aortography, angiography, and positron emission tomography [PET]) is limited.

Ultrasonography

Although segments of the ascending aorta, aortic arch, descending thoracic aorta, and proximal abdominal aorta can be visualized by transthoracic echocardiography, the atherosclerotic plaque cannot be fully evaluated by this technique. Two-dimensional (2D) transesophageal echocardiography (TEE) has historically been the primary echocardiographic

method for visualizing atherosclerotic plaques in the thoracic aorta and remains the imaging gold standard for this indication [19, 20]. During certain cardiovascular surgeries, 2D TEE may be substituted by epiaortic ultrasonography (EAU), in which the probe is placed directly on the external surface of the aorta. EAU has been used in guiding cannulation and cross-clamping of the aorta during cardiopulmonary bypass [21].

On 2D TEE or EAU, aortic plaques may be classified into mild, moderate, and severe based on plaque thickness and the appearance of the luminal surface of the plaque. Mild plaques typically have a thickness of 1.0 mm or less. Moderate plaques are usually defined as having a thickness of 1.1 to 3.9 mm. Severe plaques are often defined as having a thickness of 4 mm or more [22]. In some studies, the cutoff for severe plaque was defined differently, at either 3 or 5 mm [23].

Plaques are referred to as complex when there are ulcerations or mobile components (which represent adherent thrombi) on their luminal surface. Histologically, mild, moderate, and some severe plaques correspond mostly to stage IV (atheroma) and stage IV (fibroatheroma) lesions. Severe complex plaques, on the other hand, correspond to stage IV lesions.

The recently introduced real-time three-dimensional TEE provides images of atherosclerotic plaque in high detail. Due to the novelty of the technique, there is a paucity of data on clinical utility of this new imaging technique.

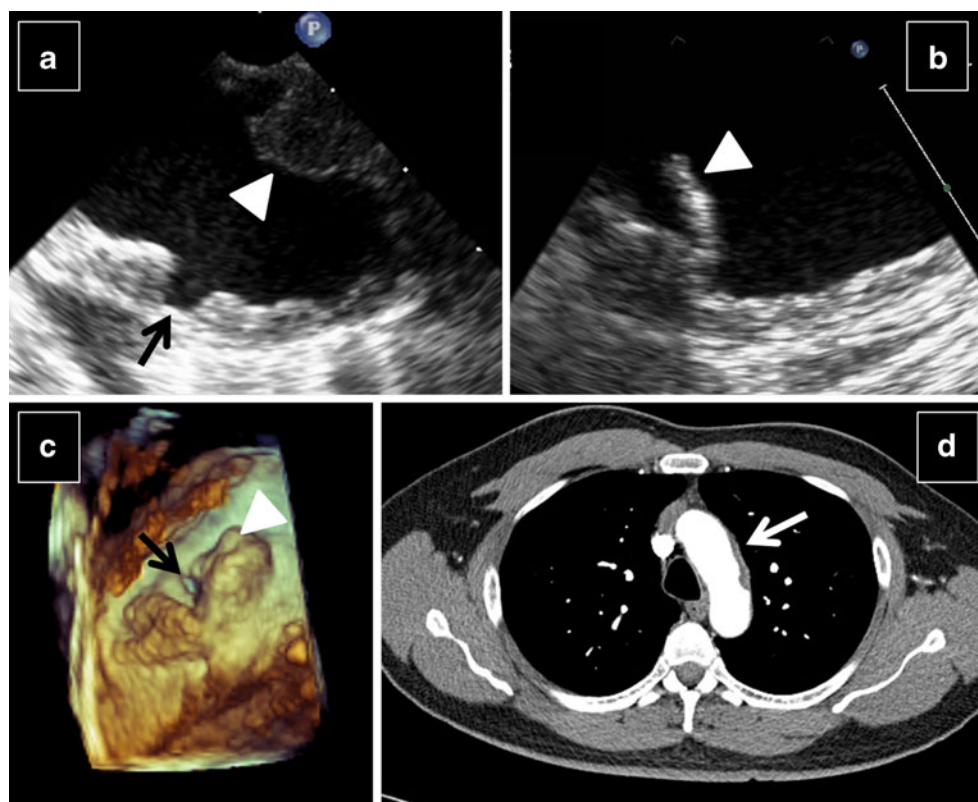
CT and MRI

Aortic atherosclerotic plaque can also be visualized by CT [24] and MRI [25]. An important advantage of CT and MRI over TEE is in their ability to visualize aortic branches, the abdominal aorta, and the portion the aortic arch around the brachiocephalic artery that is a blind spot on TEE due to interposition of the trachea between the aorta and the ultrasound probe in the esophagus. Clinical and outcomes data for CT and MRI are less robust than those for 2D TEE in assessment of aortic atherosclerosis and its embolic complications. Compared to 2D TEE, CT angiography is less sensitive for detection of thoracic aortic plaque [26]. To date there are no published large-scale comparisons of MRI to 2D TEE in patients with presumed aortic embolism. Examples of aortic plaque seen on various imaging techniques are given in Fig. 1.

Other Imaging Techniques

Aortography has been demonstrated to underestimate the extent of aortic plaque burden compared to 2D TEE [27]. The use of PET scanning in visualizing aortic plaque remains largely experimental. PET attempts to measure metabolic

Fig. 1 Visualization of aortic plaque. **a** and **b**, Complex atherosclerotic plaque in the descending thoracic aorta seen on two-dimensional transesophageal echocardiography (TEE). In **a**, the plaque is very thick, protrudes into the lumen (*white arrowhead*), and demonstrates an ulcer (*black arrow*). In **b**, the plaque contains a mobile component (*white arrowhead*) indicative of a thrombus. **c**, Complex atherosclerotic plaque seen on three-dimensional TEE. This protruding plaque (*white arrowhead*) is also ulcerated (*black arrow*). **d**, Severe plaque in the aortic arch (*white arrow*) seen on contrast-enhanced chest computed tomography. (**Panel d** is courtesy of Dr. M. Barbara Srichai-Parsia, New York University Medical Center, New York, NY)



activity within the plaque that may correlate with plaque vulnerability (propensity to rupture) and embolic potential [28].

Clinical Manifestations

Clinical presentation of aortic embolism depends on the location of an embolus-forming plaque in the aorta, embolus type (thromboembolus vs. atheroembolus), and the arterial bed to which the embolus travels.

Plaque Location

The more distal the embolus-receiving aortic branch is, the larger the area of the aorta from which plaque embolus can arise. Embolism into the arterial circulation of the lower extremities may arise in any portion of the aorta. Emboli in the splanchnic and renal arterial circulation may originate anywhere in the thoracic aorta or the very proximal abdominal aorta. Plaques in the ascending aorta and the aortic arch may lead to embolism in the coronary, cerebral, and upper extremity arterial circulation as well as to embolism to more distal aortic branches. It is also possible that material from plaques in the descending thoracic aorta may also embolize retrogradely into the aortic arch vessels during aortic flow reversal in diastole [29]. Skin embolism may arise from plaque in any portion of the thoracoabdominal aorta.

Embolus Content

As pointed out earlier, aortic embolism may take the form of either thromboembolism or atheroembolism. Given the overlapping risk factors, the same patient at times may have manifestations of both thromboembolism and atheroembolism.

In thromboembolism, clot fragments from the surface of stage VI lesions embolize to distant circulation. Clinically, thromboembolism from the aorta is usually characterized by a sudden onset of severe signs and symptoms related to occlusion of moderate to large-sized arteries (e.g., coronary, cerebral, renal or popliteal) by macroemboli. Maximum organ deficits are commonly seen at the very onset of symptoms due to abrupt occlusion of a large vascular bed.

This is contrast to atheroembolism (cholesterol embolization syndrome) in which microemboli (primarily cholesterol crystals) originating from the plaque's lipid core travel in repetitive waves (showers of emboli) to occlude arterioles whose diameter is typically 200 μm or less. Cholesterol emboli cause foreign body inflammatory reaction in the destination vascular bed. Clinically, cholesterol embolization syndrome presents often insidiously as a combination of nonspecific acute inflammatory response (fever, malaise, hypereosinophilia, eosinophiluria, elevated erythrocyte sedimentation rate) and organ-specific manifestations [30].

Thromboembolism is clinically much more prevalent than atheroembolism. For instance, in a 3-year follow-up

of patients with complex aortic plaque seen on 2D TEE the rate of thromboembolism was 20 % while that of atheroembolism was only 1 % [31].

Embolus Destination Bed

Organ-specific clinical manifestations of aortic embolism are discussed below.

Neurologic Manifestations

Neurologic manifestations (e.g., stroke and transient ischemic attacks [TIAs]) are among the most important clinical aspects of aortic embolism. Stroke in general is the leading cause of morbidity and mortality in the United States and other developed countries. Some 87 % of strokes are ischemic and 13 % are hemorrhagic [32]. Ischemic strokes are further subdivided according to the TOAST (Trial of Org 10172 in Acute Stroke Treatment) classifications into: 1) large artery atherothrombotic strokes (approximately 20 % of all ischemic strokes) mostly due to embolism from the carotid arteries or the aorta; 2) small-vessel or lacunar strokes (25 %); 3) cardioembolic strokes (20 %), most of which are related to atrial fibrillation; 4) strokes due to known but rare causes (5 %); and 5) cryptogenic strokes (strokes of unknown etiology, 30 %) [33]. Mechanistically, embolism may be implicated in several TOAST categories (e.g., large-artery strokes, cardioembolism, and likely some forms of cryptogenic stroke).

Historically, as late as the 1950s some 55 % of all strokes were believed to be secondary to cerebral vasospasm. This unproven theory was put to rest when the Canadian neurologist C. Miller Fisher, working at Harvard, clearly demonstrated the etiologic role of arterio-arterial embolization of carotid plaques in the pathophysiology of TIAs and strokes [34]. C. Miller Fisher gave clinical credence to the first accurate description on the pathophysiology of cerebral embolism from the carotid artery noted on autopsies half a century earlier by the Austro-Hungarian pathologist Hans Chiari [35].

The introduction of echocardiography opened up a new window in the evaluation of patients with embolic stroke. 2D TEE became widely available in the early 1980s and was soon used to evaluate for possible source of emboli in patients with ischemic strokes [36]. Until the 1990s, carotid atherosclerosis and atrial fibrillation were considered the two main conditions that appeared to result in TIAs, stroke, and systemic peripheral embolization. Interestingly, up to 40 % of patients with embolic workup did not reveal evidence of atrial fibrillation, carotid atherosclerosis, or any other identifiable cause; such strokes were deemed cryptogenic [37].

In 1990, physicians at the New York University echocardiography laboratory were the first to postulate a relationship between aortic atherosclerotic plaques in the aorta seen on 2D TEE and systemic embolism. In their initial report they described three patients with embolic events: a 68-year-old woman with embolus to the foot; a 77-year-old woman with cerebellar infarction after cardiac catheterization; and a 70-year-old man with staggering, diplopia, and a visual field cut. On 2D TEE, all three had severe atherosclerotic plaque in the aortic arch. In addition, freely mobile projections were seen superimposed on the plaque, making plaque content embolism a plausible cause of these patients' embolic events [38].

This initial report was followed by other case reports, series of patients, and prospective and retrospective studies. Most of these studies suggested that the 2D TEE finding of protruding plaque of greater than 3-mm thickness, as well as plaques with mobile components (complex plaques), are associated with history of embolic strokes and peripheral embolization. Furthermore, complex plaque in the aortic arch predicted a high risk of vascular events (up to 30 % per year) and stroke (12 % per year). These observations lead to a conclusion that the proportion of ischemic strokes attributable to complex aortic plaques may be similar to that attributable to either atrial fibrillation or carotid atherosclerosis [11, 39]. Subsequent pathoanatomic studies demonstrated that most mobile plaque components seen on 2D TEE represent thrombi [40].

Neurologic damage from aortic thromboembolism shares clinical similarities with other forms of macroembolism to cerebral circulation (e.g., embolism from cardiac masses or carotid plaques). Clinically, there is an abrupt onset of neurologic symptoms typical of TIAs or strokes that are due to often extensive infarcts in cortical or striatocapsular regions of the brain in the territory of the affected cerebral artery.

In contrast, neurologic manifestations of aortic atheroembolism due to showers of cholesterol emboli originating in the ascending aorta and the aortic arch are more protean. Atheroembolism typically leads to diffuse brain injury, often characterized by confusion and memory loss rather than focal neurological deficits. Brain imaging typically reveals small ischemic lesions and border zone infarcts [41].

Ocular Manifestations

Aortic thromboembolism may lead to visual field loss due to occlusion of retinal arteries, which clinically presents as amaurosis fugax (fleeting blindness). In contrast, aortic atheroembolism leads to cholesterol crystal emboli in the retinal arterioles, which are referred to as Hollenhorst plaque after the Mayo Clinic ophthalmologist who first described them [42]. On funduscopy, Hollenhorst plaques appear as highly reflective yellowish particles at branching points of

retinal arterioles. Hollenhorst plaques may be asymptomatic in as many as one third of the patients [43].

Renal Manifestations

Aortic thromboembolism into the renal artery and its large branches may lead to clinically silent or overt renal infarcts that are typically wedge-shaped. In contrast, atheroembolism obliterates the small arcuate and interlobar branches. Renal atheroembolism may lead to acute or chronic failure, and may be characterized by proteinuria, eosinophiluria, and hard-to-control hypertension. Aortic embolism should always be in the differential diagnosis of a patient who develops new or worsening renal failure after a vascular procedure involving the suprarenal aorta [44].

Gastrointestinal Manifestations

Aortic thromboembolism may lead to splenic infarct or gut ischemia, which may lead to severe, potentially life-threatening complications such as acute ischemic colitis, viscus perforation, or significant gastrointestinal bleed. Aortic atheroembolism, on the other hand, usually leads to superficial mucosal erosions due to small mucosal infarcts and often chronic blood loss. Occasionally, aortic embolism may be implicated in the pathophysiology of acalculous necrotizing cholecystitis or acute pancreatitis [45].

Skin Manifestations

Skin manifestations of aortic thromboembolism typically affect the lower extremities and the trunk. Aortic thromboembolism may lead to occlusion of large pelvic and leg arteries and secondary skin changes due to acute leg ischemia (e.g., cold and pale skin). Typically, there are pulse deficits in the leg affected by aortic thromboembolism. On the other hand, atheroembolism may lead to livedo reticularis, blue toes, skin ulcers, gangrene, or petechiae typically in the setting of relatively preserved lower-extremity pulses [46]. Blue toes are such a prevalent finding that the term blue toe syndrome (which was first described in 1976) is almost synonymous with atheroembolism and cholesterol embolization syndrome [47].

Treatment

There have been no published randomized trials to guide the therapy of aortic embolism. Proposed strategies include risk modification, and medical, surgical, and interventional therapy.

Risk Modification

Aortic embolism occurs in the larger context of atherosclerosis. Risk modification strategies (including smoking cessation, blood pressure control, and appropriate management of diabetes mellitus) have been shown to retard further progression of atherosclerosis. This, in turn, may indirectly prevent aortic embolism.

Medical Therapy

In acute thromboembolism to the cerebral circulation, thrombolytic agents may be used to recanalize the affected vessel. Proposed maintenance medical therapies for aortic embolism include antiplatelet agents and statins. No clinical trial has specifically addressed the use of antiplatelet agents in patients with aortic embolism. Recommendations to use antiplatelet agents in such patients are based on general guidelines for secondary prevention of atherosclerosis-related events. Similarly, no randomized trial of statin use in patients with aortic embolism has been published. However, many patients with aortic embolism already have strong indication for statin use (e.g., for secondary prevention of myocardial infarction or strokes).

The use of anticoagulation in patients with aortic plaques (including those with mobile components known to represent thrombi) is controversial. Small-scale studies have shown either harmful or beneficial effects of anticoagulation in patients with aortic plaques. The ongoing open-label ARCH (Aortic Arch-Related Cerebral Hazard) trial is testing the utility of full-dose anticoagulation with warfarin versus a combination of low-dose aspirin (75 mg/day) and clopidogrel (75 mg/day) for secondary prevention of vascular events in patients with aortic atheroma [48].

Surgical and Interventional Therapy

In the acute setting of aortic thromboembolism, interventional therapy may be used to manage end-organ ischemia (e.g., percutaneous intervention to open a cerebral artery containing a thromboembolus). Endarterectomy, arterial bypass surgery, and covered stents have been used in a small number of patients with aortic embolism with limited success. The 2010 ACCF/AHA/AATS/ACR/ASA/SCA/SCAI/SIR/STS/SVM guidelines on the management of thoracic aortic disease state there is insufficient evidence to recommend either endarterectomy or aortic stenting for stroke prevention in patients with aortic plaques [8••]. Endovascular stenting for treatment of aortic and arterial embolism has largely been limited to abdominal aortic and infrainguinal forms of the disease [49].

Conclusions

Aortic plaques are a general manifestation of atherosclerosis, a lifelong disorder characterized by progressive accumulation of cholesterol and other atherogenic lipids in the intimal and medial layers of the aorta and its branches. Advanced atherosclerotic lesions include atheroma, fibroatheroma, and complex atheroma with surface erosions and luminal thrombi. The clinical significance of aortic atherosclerosis lies primarily in its embolic potentials. Two types of emboli may arise from advanced aortic plaques: 1) thromboemboli, which are relatively large and made up of thrombi that were once attached to the luminal surface of the plaque; and 2) atheroemboli (also known as cholesterol crystal emboli), which arise from lipid core that ruptured and extruded its content into the aortic lumen.

Clinical manifestations of aortic thromboembolism include sudden onset of severe signs and symptoms in a large vascular territory due to occlusion of large to medium-sized arteries; examples include stroke, TIAs, myocardial infarction, renal or splenic infarcts, etc. Clinical manifestations of cholesterol crystal embolism are more protein and are due to occlusion of mostly small arteries and arterioles; examples include blue toe syndrome, new or worsening renal failure, confusion, memory loss, etc.

There are no proven medical or surgical therapies for the prevention of either form of aortic embolism. Proposed treatment strategies include atherosclerosis risk modification, antiplatelet agents, statins, endarterectomy, and aortic stenting. The use of anticoagulants in aortic embolism is controversial.

Disclosure Conflicts of interest: M. Saric: none; I. Kronzon: has received honoraria from Philips Healthcare.

References

Papers of particular interest, published recently, have been highlighted as:

- Of importance
- Of major importance

1. Haller, Albrecht von. *Observatio XXXVII: materia ossium morbosorum*. In: *Opuscula pathologica*. Lausanne: Bousquet; 1755. p. 124–8.
2. Lobstein JGCFM. *Traité d'anatomie pathologique*. Paris: Chez F. G. Levrault; 1833. p. 550–3.
3. Marchand JF. Über arteriosklerose (athero-sklerose). *Verh Kongresses Innere Medizin*. 1904;21:23–59.
4. Expert Panel on Detection, Evaluation, and Treatment of High Blood Cholesterol in Adults: executive summary of the third report of the National Cholesterol Education Program (NCEP) Expert

- Panel on Detection, Evaluation, and Treatment of High Blood Cholesterol in Adults (ATP III). *JAMA*. 2001;285:2486–249.
5. Selzman CH, Miller SA, Harken AH. Therapeutic implications of inflammation in atherosclerotic cardiovascular disease. *Ann Thorac Surg*. 2001;71(6):2066–74.
6. Danesh J, Lewington S, Thompson SG, et al. Plasma fibrinogen level and the risk of major cardiovascular diseases and nonvascular mortality: an individual participant meta-analysis. *JAMA*. 2005;294(14):1799–809.
7. Stary HC, Chandler AB, Dinsmore RE, Fuster V, Glagov S, Insull Jr W, Rosenfeld ME, Schwartz CJ, Wagner WD, Wissler RW. A definition of advanced types of atherosclerotic lesions and a histological classification of atherosclerosis. A report from the Committee on Vascular Lesions of the Council on Arteriosclerosis, American Heart Association. *Circulation*. 1995;92(5):1355–74.
8. •• Hiratzka LF, Bakris GL, Beckman JA, Bersin RM, Carr VF, Casey DE Jr, Eagle KA, Hermann LK, Isselbacher EM, Kazerooni EA, Kouchoukos NT, Lytle BW, Milewicz DM, Reich DL, Sen S, Shinn JA, Svensson LG, Williams DM; American College of Cardiology Foundation/American Heart Association Task Force on Practice Guidelines; American Association for Thoracic Surgery; American College of Radiology; American Stroke Association; Society of Cardiovascular Anesthesiologists; Society for Cardiovascular Angiography and Interventions; Society of Interventional Radiology; Society of Thoracic Surgeons; Society for Vascular Medicine. 2010 ACCF/AHA/AATS/ACR/ASA/SCA/SCAI/SIR/STS/SVM Guidelines for the diagnosis and management of patients with thoracic aortic disease. A Report of the American College of Cardiology Foundation/American Heart Association Task Force on Practice Guidelines, American Association for Thoracic Surgery, American College of Radiology, American Stroke Association, Society of Cardiovascular Anesthesiologists, Society for Cardiovascular Angiography and Interventions, Society of Interventional Radiology, Society of Thoracic Surgeons, and Society for Vascular Medicine. *J Am Coll Cardiol*. 2010 Apr 6;55(14):e27–129. *This paper provides an extensive review of aortic atherosclerosis and the latest guidelines for its management.*
9. Golledge J, Norman PE. Atherosclerosis and abdominal aortic aneurysm: cause, response, or common risk factors? *Arterioscler Thromb Vasc Biol*. 2010;30(6):1075–7.
10. • Kronzon I, Saric M. Cholesterol embolization syndrome. *Circulation*. 2010;122:631–41. *This article provides an exhaustive review of cholesterol embolization syndrome, which together with thromboembolism, is the major manifestation of aortic atherosclerosis.*
11. Tunick PA, Kronzon I. Atheromas of the thoracic aorta: clinical and therapeutic update. *J Am Coll Cardiol*. 2000;35:545–54.
12. Fenger CE, Jacobsen JP, Dahlerup EA, Hornemann E, Collin T. Beretning af Obduktionen over Albert Thorvaldsen (autopsy report of Albert Thorvaldsen). *Ugeskr Laeger*. 1844;X(14–15):215–8.
13. Panum PL. Experimentelle Beiträge zur Lehre von der Embolie. *Virchows Arch Pathol Anat Physiol*. 1862;25:308–10.
14. Tunick PA, Katz ES, Freedberg RS, Rosezweig BP, Perez JL, Kronzon I. High risk vascular events in patients with protruding aortic atheromas: a prospective study. *J Am Coll Cardiol*. 1994;23:1085–90.
15. Stern A, Tunick PA, Culliford AT, Lachmann J, Baumann FG, Kanchuger M, Marschall K, Shah A, Grossi E, Kronzon I. Protruding aortic arch atheromas: risk of stroke during heart surgery with and without aortic arch endarterectomy. *Am Heart J*. 1999;138:746–52.
16. Rodés-Cabau J, Dumont E, Boone RH, Larose E, Bagur R, Gurvitch R, Bédard F, Doyle D, De Larocheillère R, Jayasuria C, Villeneuve J, Marrero A, Côté M, Pibarot P, Webb JG. Cerebral embolism following transcatheter aortic valve implantation: comparison of transfemoral and transapical approaches. *J Am Coll Cardiol*. 2011;57(1):18–28.

17. Szeto WY, Augoustides JG, Desai ND, Moeller P, McGarvey ML, Walsh E, Bannan A, Herrmann HC, Bavaria JE. Cerebral embolic exposure during transfemoral and transapical transcatheter aortic valve replacement. *J Card Surg.* 2011;26(4):348–54.
18. Saric M, Kronzon I. Cholesterol embolization syndrome. *Curr Opin Cardiol.* 2011;26:472–9.
19. Rana BS, Monaghan MJ, Ring L, Shapiro LS, Nihoyannopoulos P. The pivotal role of echocardiography in cardiac sources of embolism. *Eur J Echocardiogr.* 2011;12(10):i25–31.
20. •• Pepi M, Evangelista A, Nihoyannopoulos P, Flachskampf FA, Athanassopoulos G, Colonna P, Habib G, Ringelstein EB, Sicari R, Zamorano JL, Sitges M, Caso P; European Association of Echocardiography. Recommendations for echocardiography use in the diagnosis and management of cardiac sources of embolism: European Association of Echocardiography (EAE) (a registered branch of the ESC). *Eur J Echocardiogr.* 2010 Jul;11(6):461–76. *These are the latest guidelines for the use of echocardiography for the detection of cardiac and aortic sources of emboli.*
21. Davila-Roman VG, Phillips KJ, Daily BB, Davila RM, Kouchoukos NT, Barzilai B. Intraoperative transesophageal echocardiography and epiaortic ultrasound for assessment of atherosclerosis of the thoracic aorta. *J Am Coll Cardiol.* 1996;28:942–7.
22. Amarenco P, Cohen A, Tzourio C, Bertrand B, Hommel M, Besson G, Chauvel C, Touboul PJ, Boussier MG. Atherosclerotic disease of the aortic arch and the risk of ischemic stroke. *N Engl J Med.* 1994;331(22):1474–9.
23. Sharma U, Tak T. Aortic atheromas: current knowledge and controversies: a brief review of the literature. *Echocardiogr.* 2011;28(10):1157–63.
24. Ko Y, Park JH, Yang MH, Ko SB, Choi SI, Chun EJ, Han MK, Bae HJ. Significance of aortic atherosclerotic disease in possibly embolic stroke: 64-multidetector row computed tomography study. *J Neurol.* 2010;257(5):699–705.
25. Zahuranec DB, Mueller GC, Bach DS, Stojanovska J, Brown DL, Lisabeth LD, Patel S, Hughes RM, Attili AK, Armstrong WF, Morgenstern LB. Pilot study of cardiac magnetic resonance imaging for detection of embolic source after ischemic stroke. *J Stroke Cerebrovasc Dis.* 2011 Jun 1. [Epub ahead of print].
26. Barazangi N, Wintermark M, Lease K, Rao R, Smith W, Josephson SA. Comparison of computed tomography angiography and transesophageal echocardiography for evaluating aortic arch disease. *J Stroke Cerebrovasc Dis.* 2011;20(5):436–42.
27. Khatri IA, Mian N, Al-Kawi A, Janjua N, Kirmani JF, Saric M, Levine JC, Qureshi AI. Arch aortogram fails to identify aortic atherosclerotic lesions detected on transesophageal echocardiogram. *J Neuroimaging.* 2005;15:1–5.
28. Dunphy MP, Freiman A, Larson SM, Strauss HW. Association of vascular 18F-FDG uptake with vascular calcification. *J Nucl Med.* 2005;46(8):1278–84.
29. Harloff A, Simon J, Brendecke S, Assefa D, Helbing T, Frydrychowicz A, Weber J, Olschewski M, Strecker C, Hennig J, Weiller C, Markl M. Complex plaques in the proximal descending aorta: an underestimated embolic source of stroke. *Stroke.* 2010;41(6):1145–50.
30. Saric M, Kronzon I. Embolism from aortic plaque: atheroembolism (cholesterol crystal embolism). In: Basow DS, editor. *UpToDate.* Waltham: UpToDate; 2011.
31. Tunick PA, Nayar AC, Goodkin GM, Mirchandani S, Francescone S, Rosenzweig BP, Freedberg RS, Katz ES, Applebaum RM, Kronzon I. Effect of treatment on the incidence of stroke and other emboli in 519 patients with severe thoracic aortic plaque. *Am J Cardiol.* 2002;90:1320–5.
32. American Heart Association website: http://www.strokeassociation.org/STROKEORG/AboutStroke/About-Stroke_UCM_308529_SubHomePage.jsp accessed February 25, 2012.
33. Adams Jr HP, Bendixen BH, Kappelle LJ, Biller J, Love BB, Gordon DL, Marsh 3rd EE. Classification of subtype of acute ischemic stroke. Definitions for use in a multicenter clinical trial. TOAST. Trial of Org 10172 in Acute Stroke Treatment. *Stroke.* 1993;24(1):35–41.
34. Estol CJ, Dr C. Miller Fisher and the history of carotid artery disease. *Stroke.* 1996;27(3):559–66.
35. Chiari H. Ueber Verhalten des Teilungswinkels der Carotis Communis bei der Enderteritis Chronica Deformans. *Verh Dtsch Ges Pathol.* 1905;9:326.
36. Kronzon I, Tunick PA. Transesophageal echocardiography as a tool in the evaluation of patients with embolic disorders. *Prog Cardiovasc Dis.* 1993;36:39–60.
37. Sacco RL, Ellenberg JH, Mohr JP, Tatemichi TK, Hier DB, Price TR, Wolf PA. Infarcts of undetermined cause: the NINCDS stroke data bank. *Ann Neurol.* 1989;25:382–90.
38. Tunick PA, Kronzon I. Protruding atherosclerotic plaque in the aortic arch of patients with systemic embolization: a new finding seen by transesophageal echocardiography. *AM Heart J.* 1990;120:658–60.
39. Kronzon I, Tunick PA. Atheromatous disease of the thoracic aorta: pathologic and clinical implications. *Ann Intern Med.* 1997;126:629–37.
40. Vaduganathan P, Ewton A, Nagueh SF, Weilbaecher DG, Safi HJ, Zoghbi WA. Pathologic correlates of aortic plaques, thrombi and mobile “aortic debris” imaged in vivo with transesophageal echocardiography. *J Am Coll Cardiol.* 1997;30(2):357–63.
41. Ezzeddine MA, Primavera JM, Rosand J, Hedley-Whyte ET, Rordorf G. Clinical characteristics of pathologically proved cholesterol emboli to the brain. *Neurology.* 2000;54:1681–3.
42. Hollenhorst RW. Significance of bright plaques in the retinal arterioles. *JAMA.* 1961;178:23–9.
43. Bunt TJ. The clinical significance of the asymptomatic Hollenhorst plaque. *J Vasc Surg.* 1986;4(6):559–62.
44. Scolari F, Ravani P, Gaggi R, Santostefano M, Rollino C, Stabellini N, Colla L, Viola BF, Maiorca P, Venturelli C, Bonardelli S, Faggiano P, Barrett BJ. The challenge of diagnosing atheroembolic renal disease: clinical features and prognostic factors. *Circulation.* 2007;116:298–304.
45. Moolenaar W, Lamers CBHW. Cholesterol crystal embolization and the digestive system. *Scand J Gastroenterol.* 1991;26 suppl 188:69–72.
46. Falanga V, Fine MJ, Kapoor WN. The cutaneous manifestations of cholesterol crystal embolization. *Arch Dermatol.* 1986;122:1194–9.
47. Karmody AM, Powers SR, Monaco VJ, Leather RP. ‘Blue toe’ syndrome: an indication for limb salvage surgery. *Arch Surg.* 1976;111:1263–8.
48. <http://clinicaltrials.gov/ct2/show/NCT00235248> Accessed February 25, 2012.
49. Wolf PS, Burman HE, Starnes BW. Endovascular treatment of massive thoracic aortic thrombus and associated ruptured atheroma. *Ann Vasc Surg.* 2010;24(3):416.e9–416.e12.