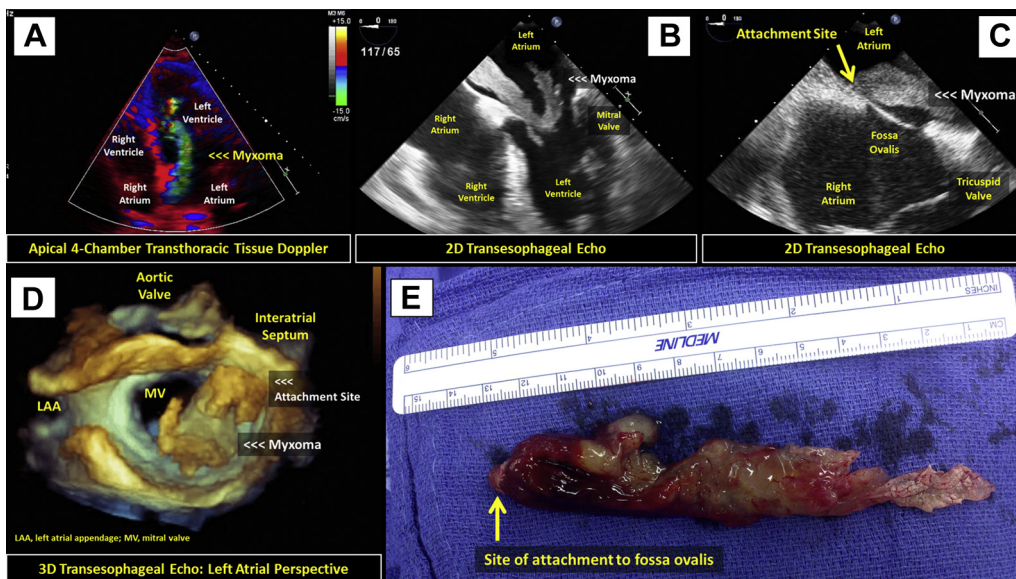


IMAGES IN CARDIOLOGY

# Giant Nonfamilial Left Atrial Myxoma Presenting With Eye Embolism and Nonvalvular *Streptococcus sanguinis* Endocarditis



Diana M. Laura, BA, Adriana Quiñones, MD, Ricardo Benenstein, MD, Didier F. Loulmet, MD, William J. Cole, MD, Dellis A. Galloway, MD, James H. Suh, MD, Muhamed Saric, MD, PhD  
*New York, New York*



From New York University  
Langone Medical Center,  
New York, New York.  
Manuscript received  
November 27, 2013;  
accepted December 3, 2013.

**A** 64-year-old man developed a 3-month history of recurrent fatigue, fevers, and leukocytosis after teeth cleaning. A year earlier, he had experienced sudden vision loss in the left eye, believed to be nonarteritic anterior ischemic neuropathy.

Two-dimensional (2D) and 3-dimensional (3D) transthoracic and transesophageal echocardiography revealed a shaggy, highly mobile, 13.0 × 1.5 cm sausage-like mass in the left heart (**A and B**, [Online Video 1](#)). The mass prolapsed intermittently through the mitral valve into the left ventricle and was tethered to the interatrial septum near the fossa ovalis (**C and D**, [Online Videos 2 and 3](#)). Neither significant mitral regurgitation nor mitral stenosis was observed. Blood cultures grew *Streptococcus sanguinis*.

The patient underwent surgical removal of the mass (**E**, [Online Video 4](#)). Histopathology revealed left atrial myxoma superinfected with *S sanguinis*. Despite the giant tumor size and its plop through the mitral valve, the myxoma was clinically silent until it led to subacute nonvalvular infective endocarditis and likely prior ocular embolism.