

Mitral Bioprosthetic Valve Endocarditis Caused by an Unusual Microorganism, *Gemella morbillorum*, in an Intravenous Drug User

Ramzan M. Zakir, Anthony Al-Dehneh, Leticia Dabu, Raj Kapila, and Muhamed Saric*

Department of Medicine, New Jersey Medical School, Newark, New Jersey

Received 29 March 2004/Accepted 11 May 2004

We report a case of *Gemella morbillorum* mitral bioprosthetic valve endocarditis with perivalvular extension in a 44-year-old human immunodeficiency virus-positive man who is an active intravenous drug user together with review of all published cases. This is only the second reported case of *Gemella morbillorum* endocarditis in a patient with a prosthetic valve.

CASE REPORT

A 44-year-old human immunodeficiency virus-positive man with a history of active intravenous drug use and a mitral valve replacement only 9 months earlier for native-valve endocarditis due to *Staphylococcus aureus* was admitted complaining of pleuritic chest pain, shortness of breath, fever, and chills.

Physical examination revealed a temperature of 99.8°F, blood pressure of 114/70 mm Hg, a regular heart rate at 98 beats per min, and a grade III/VI holosystolic murmur radiating to the axilla. No clinical signs of congestive heart failure (such as pulmonary rales or peripheral edema) were noted.

An electrocardiogram was notable for a first-degree atrioventricular block (an increased PR interval of 0.22 s) and nonspecific T wave changes. Laboratory investigations were significant for a normocytic anemia with a hemoglobin level of 10.9 g/dl and an elevated erythrocyte sedimentation rate of 108 mm per h. However, neither the total white blood cell count nor the percentage of banded neutrophils was elevated (3.72×10^9 /liter and 4% bands, respectively).

Three sets of blood cultures were obtained prior to initiating antibiotic therapy. Blood samples were incubated in a continuous-monitoring culture system (Bac T/Alert; Becton Dickinson, Organon Teknika, Durham, N.C.) at 37°C. After 24 h of incubation, growth in the anaerobic bottle was noted. The samples were then subcultured at 37°C on MacConkey's agar, sheep blood agar, anaerobic CDC blood agar, and chocolate agar incubated in CO₂.

After 24 h of subculture incubation, an alpha-hemolytic organism grew on all plates except the MacConkey agar. The organism was further characterized as being a gram-positive coccus that was both catalase and bile solubility negative.

These initial findings suggested that the organism was *Streptococcus viridans*. However, on further evaluation with an API 20 streptococcus identification system (Bio Merieux, Vitek

Inc., Hazelwood, Mo.), the organism was identified as *Gemella morbillorum* with 98% confidence.

Antimicrobial susceptibility by disk diffusion method showed the organism to be sensitive to ceftriaxone, clindamycin, levofloxacin, tetracycline, and vancomycin, while the Etest showed sensitivity to penicillin G.

A transthoracic echocardiogram revealed severe regurgitation through incompetent leaflets of the bioprosthetic mitral valve. On spectral Doppler recording of the prosthetic inflow, a severely elevated mean diastolic gradient of 22 mm Hg at a sinus heart rate of 75 beats per min was noted. Since there were no echocardiographic signs of prosthetic stenosis (the pressure half-time was only 77 ms), this gradient was indicative of severely elevated left atrial pressure due to severe mitral regurgitation. In addition, there was moderate central aortic insufficiency.

The left atrium was enlarged (5.3 cm in diameter), as was the left ventricle (end diastolic diameter of 5.8 cm). The left ventricular ejection fraction was high normal (65 to 70%). The imaging of the right side of the heart revealed moderate tricuspid regurgitation and elevation of right atrial (>20 mm Hg) and pulmonary artery systolic (>45 mm Hg) pressures.

On a subsequent transesophageal echocardiogram the prosthetic leaflets were thickened and studded with globular echo densities consistent with vegetations (Fig. 1). In addition, they were misshapen, leading to failure of leaflet coaptation and transvalvular regurgitation.

However, between the mitral prosthetic ring and the non-coronary cusp of the native aortic valve there was a 1-cm septated echo lucency with a fistulous tract between the left ventricular outflow tract and the left atrium, seen on color Doppler imaging. These findings were consistent with a paravalvular abscess (Fig. 2). However, there was no paravalvular mitral regurgitation.

This patient met multiple Duke criteria for a definite diagnosis of infectious endocarditis. He met two major criteria (new valvular regurgitation and positive echocardiogram) and two minor criteria (predisposing factor of intravenous drug use and a blood culture growing an organism that does not commonly cause endocarditis).

Based on the findings of severe prosthetic mitral regurgitations and a likely paraprosthetic abscess in the setting of PR

* Corresponding author. Mailing address: Echocardiography Lab, Division of Cardiovascular Diseases, New Jersey Medical School, 185 South Orange Ave., I-538, University Heights, Newark, NJ 07103. Phone: (973) 972-6084. Fax: (973) 972-4737. E-mail: saricmu@umdnj.edu.

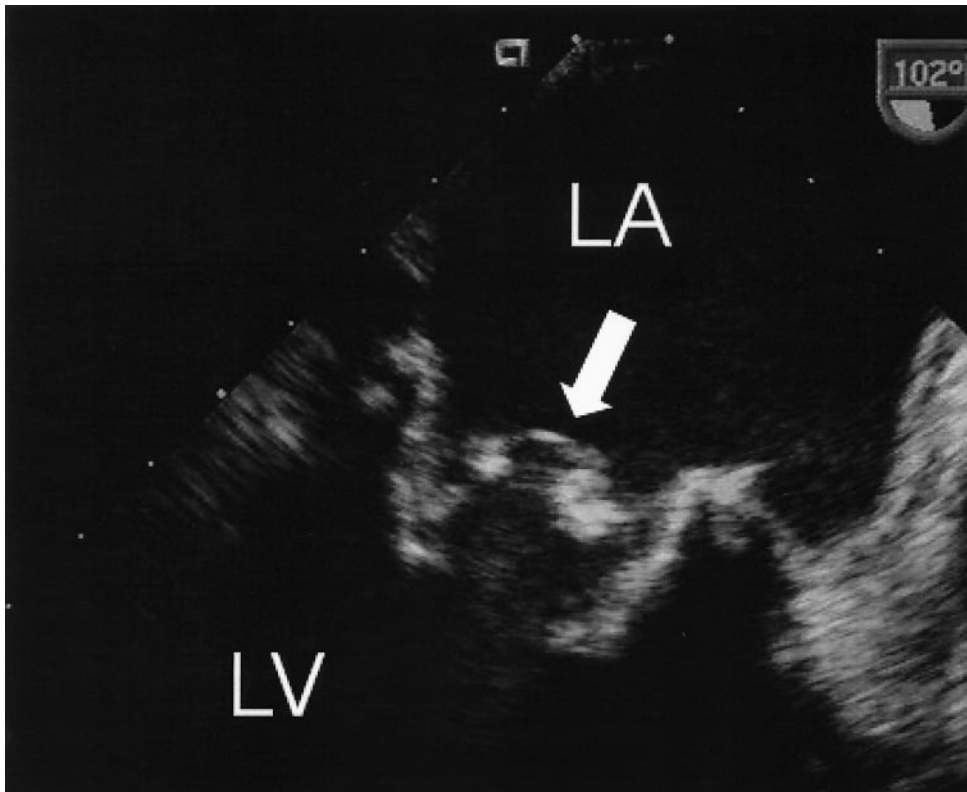


FIG. 1. Transesophageal echocardiogram of infected mitral bioprosthesis. The leaflets of the mitral bioprosthesis (arrow) are thickened and studded with globular echo densities consistent with vegetations. On color Doppler (not shown), there was severe transvalvular mitral regurgitation. LA, left atrium; LV, left ventricle.

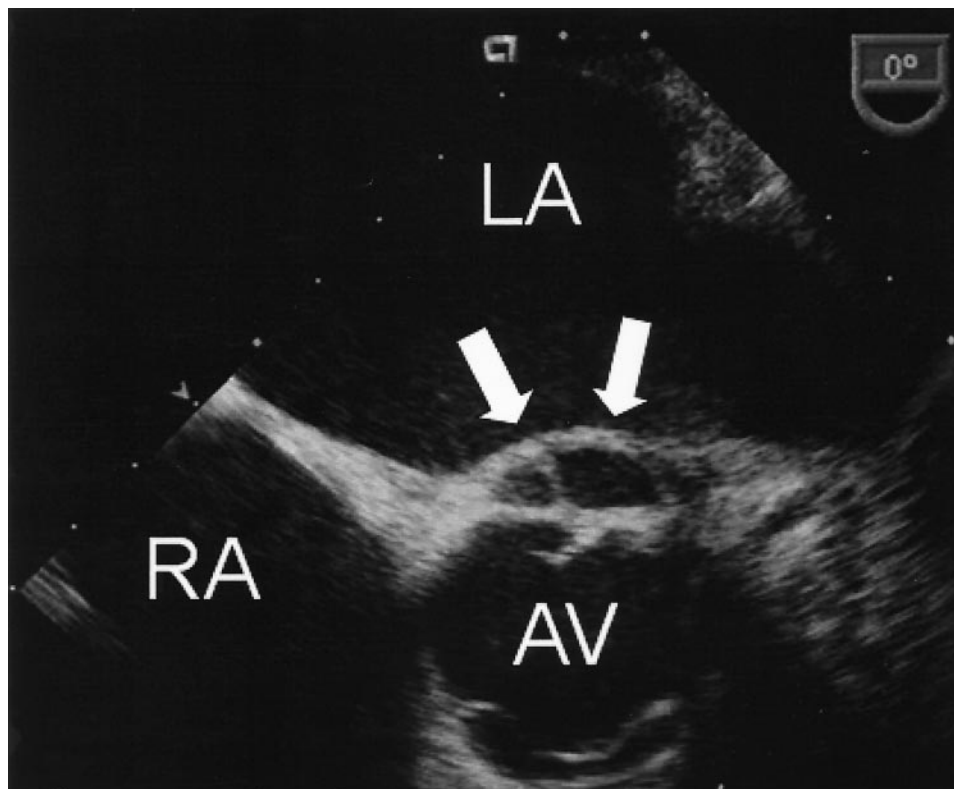


FIG. 2. Transesophageal echocardiogram of paraprosthetic abscess. Extending from the mitral bioprosthetic ring and adjacent to the native aortic valve (AV) there is a septated echo-free space (arrows), a finding indicative of abscess formation. LA, left atrium; RA, right atrium.

TABLE 1. Summary of all reported cases of *Gemella morbillorum* endocarditis^a

Type of endocarditis and case no.	Age (yr)/sex	Preexisting cardiac lesion	Cardiac structure involved in IE	Presumed source of organism	Treatment	Bacteriologic outcome	Source or reference
Native cardiac valve							
1	29/F	HOCM	Not reported	Dental	Penicillin, erythromycin, gentamicin, rifampin	Cure	15
2	39/M	Bicuspid AV	AV	Dental	AVR	Cure	20
3	74/M	None	AV	Dental	AVR	Cure	17
4	55/M	Prior IE	AV	Dental	AVR	Cure	2
5	N/A	Bicuspid AV	AV	Not reported	Not specified	Not reported	17
6	54/M	None	AV	Dental	AVR	Cure	11
7	73/F	NA	AV, MV	Colon cancer	AVR, MVR	Died (CHF)	18
8	64/M	None	AV, MV	Dental	MVR, AVR	Cure	24
9	66/M	None	AV, MV	Not reported	Penicillin, netilmicin	Cure	28
10	32/M	None	AV, MV	Intravenous drug user	MVR, AVR	Died (cardiogenic shock)	26
11	48/M	None	MV	Dental	Vancomycin	Cure	22
12	9/F	None	MV	Dental	Penicillin	Cure	12
13	75/M	Rheumatic heart disease	MV	Not reported	Penicillin, gentamicin, teicoplanin, rifampin, erythromycin	Cure	19
14	38/M	None	MV	Sigmoidoscopy	Penicillin, gentamicin	Cure	24
15	60/M	None	MV	Vascular graft	Penicillin, rifampin	Cure	8
16	41/F	None	MV	Dental	Penicillin, gentamicin	Cure	3
17	42/M	MR	MV, TV	Toxic syndrome	Penicillin, streptomycin	Cure	7
18	74/M	None	TV	Colon resection	Penicillin, ceftriaxone, amikacin	Cure	1
19	71/M	None	TV	Dental	Penicillin	Cure	21
20	19/M	None	TV	Intravenous drug user	Penicillin, gentamicin	Cure	4
21	31/M	Tetralogy of Fallot	TV	Not reported	Vancomycin, rifampin	Cure	5
Prosthetic valve							
22	84/F	Bioprosthetic (porcine)	MV, AV	Not reported	Penicillin, gentamicin	Cure	14
23	44/M	Mechanical (St. Jude)	MV	Drug abuser	Ceftriaxone, gentamicin	Cure	Present case

^a Abbreviations: AV, aortic valve; AVR, aortic valve replacement; CHF, congestive heart failure; HOCM, hypertrophic obstructive cardiomyopathy; MR, mitral regurgitation; MV, mitral valve; MVR, mitral valve replacement; TV, tricuspid valve; IE, infective endocarditis; NA, not available.

prolongation on an electrocardiogram, the patient was considered for repeat valvular surgery. However, given the patient's active drug use and a high intraoperative risk, the patient was treated instead medically with ceftriaxone for 4 weeks, with gentamicin added during the first 2 weeks of therapy. Subsequent blood cultures on therapy were all negative.

Discussion. *Gemella morbillorum*, formally *Streptococcus morbillorum*, is a catalase-negative, facultatively anaerobic gram-positive coccus that was first described in 1917 by Tunnicliff (25).

In 1988, the organism was transferred to its present genus based on DNA homology, physiologic properties, and 16S RNA cataloguing (16). It is part of the commensal flora of the oropharynx, gastrointestinal tract, and genitourinary tract and an infrequent cause of infection. Although there have been reports of *Gemella morbillorum* causing bacteremia and localized infections such as meningitis (9, 13), arthritis (22, 27), abscesses (6, 23), and septic shock (10), the organism is most commonly associated with infectious endocarditis.

Some 22 cases of endocarditis caused by *Gemella morbillorum* have been reported in English previously, with the vast majority involving native (nonprosthetic) valves. (Table 1) (1–5, 7, 8, 11, 12, 14, 15, 17–22, 24, 26, 28).

The patient ages ranged from 9 to 84 years (mean, 53 years), and most were males (Table 1). Predisposing factors included poor dental hygiene, dental procedures, and colon disease and gastrointestinal diagnostic procedures. Underlying intracardiac lesions included preexisting valvular lesions, congenitally bicuspid aortic valve (17, 20), hypertrophic cardiomyopathy (15), cardiac myxoma (27a), and tetralogy of Fallot (5). The aortic, tricuspid, and mitral valves have been affected.

To the best of our knowledge, there has been only one previous report of endocarditis due to *Gemella morbillorum* involving a prosthetic valve and only two cases associated with intravenous drug users.

In the majority of the reported cases of endovascular infections by *Gemella morbillorum*, a bacteriological cure was achieved with a combination of penicillin and an aminoglycoside. In patients that were either allergic or resistant to penicillin, vancomycin or a combination of erythromycin and rifampin has been effective (19).

In seven previously reported cases, native-valve endocarditis due to *Gemella morbillorum* was treated with surgical valve replacement (2, 11, 17, 18, 20, 24, 26). Two patients died shortly after aortic and mitral valve replacement (14, 26), but the remaining five cases had satisfactory outcomes.

To the best of our knowledge, our patient is only the second reported case of endocarditis due to *Gemella morbillorum* in a

patient with a prosthetic valve and only the third in an intravenous drug abuser.

Despite severe valvular and paravalvular complications, the patient was stable 6 months after discharge although he received no surgical therapy. This unusual recovery demonstrates a dramatic response of endocarditis due to *Gemella morbillorum* to antimicrobial therapy.

REFERENCES

1. **Abhoud, R., and A. Friart.** 1995. Deux cas d'endocardite tricuspide isolée après intervention colique. *Acta Clin. Belg.* **50**:242–245.
2. **Akiyama, K., N. Taniyasu, J. Hirota, Y. Iba, and K. Maisawa.** 2001. Recurrent aortic valve endocarditis caused by *Gemella Morbillorum*. *Jpn Circ. J.* **65**:997–1000.
3. **Al Soub, H., S. S. El-Shafie, A. L. Al-Khal, and A. M. Salam.** 2003. *Gemella morbillorum* endocarditis. *Saudi Med J.* **24**:1135–1137.
4. **Bell, E., and A. C. McCartney.** 1992. *Gemella morbillorum* endocarditis in an intravenous drug abuser. *J. Infect.* **25**:110–112.
5. **Benes, J., D. Picha, M. Kabelkova, O. Dzapova, and B. Horova.** 2002. Infective endocarditis caused by unusual gram-positive pathogens. *Folia Microbiol.* **47**:737–741.
6. **Brook, I., and E. H. Frazier.** 1994. Microaerophilic streptococci as a significant pathogen: a twelve-year review. *J. Med.* **25**:129–144.
7. **Calopa, M., F. Rubio, M. Aguilar, and J. Peres.** 1990. Giant basilar aneurysm in the course of subacute bacterial endocarditis. *Stroke* **21**:1625–1627.
8. **Coto, H., and S. L. Berk.** 1984. Endocarditis caused by *Streptococcus morbillorum*. *Am. J. Med. Sci.* **287**:54–58.
9. **Debast, S. B., R. Koot, and C. A. Meis.** 1993. Infections caused by *Gemella morbillorum*. *Lancet* **342**:560.
10. **Eltling, L. S., G. P. Bodey, and B. H. Keefe.** 1992. Septicemia and shock syndrome due to viridians streptococci: a case-control study of predisposing factors. *Clin. Infect. Dis.* **14**:1201–1207.
11. **Espinosa-Villarreal, J. G., E. Gonzalez-Reimers, M. Lecuona, M. Rodriguez-Gaspar, A. M. Lopez-Lirola, F. Rodriguez-Moreno, F. Santolaria, and C. Revert.** 2000. Endocarditis caused by *Gemella morbillorum*. *Enferm. Infecc. Microbiol. Clin.* **18**:293.
12. **Farmaki, E., E. Roilides, E. Darilis, M. Tsivitanidou, et al.** 2000. *Gemella morbillorum* endocarditis in a child. *Pediatr. Infect. Dis. J.* **19**:751–753.
13. **Garavelli, P. L.** 1990. Meningitis caused by *Streptococcus morbillorum*. *Minerva Med.* **81**:69.
14. **Holland, J., R. Wilson, and N. Cumpston.** 1996. *Gemella morbillorum* prosthetic valve endocarditis. *N Z Med. J.* **27**:367.
15. **Kerr, J. R., C. H. Webb, J. G. McGimpsey, and N. P. S. Campbell.** 1994. Infective endocarditis due to *Gemella morbillorum* complicating hypertrophic obstructive cardiomyopathy. *Ulster Med. J.* **63**:108–110.
16. **Kilpper-Balz, R., and K. H. Schleifer.** 1988. Transfer of *Streptococcus morbillorum* to the genus *Gemella* as *Gemella morbillorum* comb. nov. *Int. J. Syst. Bacteriol.* **38**:442–443.
17. **La Scola, B., and D. Raoult.** 1998. Molecular identification of *Gemella* species from three patients with endocarditis. *J. Clin. Microbiol.* **36**:866–871.
18. **Lopez-Dupla, M., C. Creus, O. Navarro, and X. Raga.** 1996. Association of *Gemella morbillorum* endocarditis with adenomatous polyps and carcinoma of the colon. Case report and review. *Clin. Infect. Dis.* **22**:379–380.
19. **Martin, M. J., D. A. Wright, and A. R. R. Jones.** 1995. A case of *Gemella morbillorum* endocarditis. *Postgrad. Med. J.* **71**:188.
20. **Maxell, S.** 1989. Endocarditis due to *Streptococcus morbillorum*. *J. Infect.* **18**:67–72.
21. **Nandakumar, R., and G. Raju.** 1997. Isolated tricuspid valve endocarditis in nonaddicted patients. A diagnostic challenge. *Am. J. Med. Sci.* **314**:207–212.
22. **Omran, Y., and C. A. Wood.** 1993. Endovascular infection and septic arthritis caused by *Gemella morbillorum*. *Diagn. Microbiol. Infect. Dis.* **16**:131–134.
23. **Pradeep, R., M. Ali, and C. F. Encarnacion.** 1997. Retropharyngeal abscess due to *Gemella morbillorum*. *Clin. Infect. Dis.* **24**:284–285.
24. **Terada, H., K. Miyahara, H. Sohara, M. Sonoda, H. Uenomachi, J. Sanada, et al.** 1994. Infective endocarditis caused by an indigenous bacterium (*Gemella morbillorum*). *Intern. Med.* **33**:628–631.
25. **Tunncliffe, R.** 1917. The cultivation of a micrococcus from blood in pre- and eruptive stages of measles. *JAMA* **68**:1028–1030.
26. **Ubeda, R. P., M. I. Gutierrez, G. P. Ramirez, B. C. Perez, and S. M. Gobernado.** 2000. Endocarditis due to *Gemella morbillorum* in a parenteral drug-abuse addict. *Rev. Clin. Esp.* **200**:176–177.
27. **von Essen, R., M. Ikavalko, and B. Forsblom.** 1993. Isolation of *Gemella morbillorum* from joint fluid. *Lancet* **342**:177–178.
- 27a. **Wang, T.-D., S.-C. Chang, I.-P. Chiang, K.-T. Luh, and Y.-T. Lee.** 1996. Infected left atrial myxoma caused by *Gemella morbillorum*. *Scand. J. Infect. Dis.* **28**:633–634.
28. **Woo, P. C., S. K. Lau, A. M. Fung, S. K. Chiu, R. W. Yung, and K. Y. Yuen.** 2003. *Gemella* bacteraemia characterized by 16S ribosomal RNA gene sequencing. *J. Clin. Pathol.* **56**:690–693.